

# Health Risks Associated with Body Piercing and Tattooing: Lesson for the Adolescent

LUKUMON AKANDE SALAHUDEEN<sup>1</sup>, ABRAHAM O. A<sup>2</sup>

<sup>1</sup>Office of the Vice Chancellor, Lagos State University

<sup>2</sup>Entrepreneurship Department, Moscow University for Industry & Finance

*Abstract -- This study examined the health risks associated with body piercing and tattooing: lesson for the young adolescent. Both theoretical and existing literature was reviewed. Information from this finding show that, Body piercing and tattooing are two categories of skin piercing, which fall within the wider phenomena of body art or modification. The study reveals that there are well reported health risks which was attributed to body piercing and tattooing which includes but not limited to Hepatitis or HIV, which can have more serious and long term health consequences. Finally, this study recommends that new needles should be used with each body piercing or tattooing and by selecting a studio with an educated artist to reduce the risk of contracting either hepatitis or HIV and also, Piercers were advised to sterilize jewelry immediately before insertion. And use soap and water as an appropriate after-care solution for cleaning and maintenance.*

*Indexed Terms -- Body, health, piercing, risk, tattooing*

## I. INTRODUCTION

The word tattoo is derived from the Tahitian word "ta-tau," which means "the results of tapping" and describes the raking process by which the Polynesians applied their tattoos. Tattooing has been prevalent for thousands of years in a variety of cultures. Tattooed mummies from Egypt, Peru and the Philippines have been radiocarbon-dated as far back as 2000 BC.

Tattooing and body piercing are flourishing and the new innovations of branding and scarification continue to develop. Even more evident is the advent of cosmetic tattooing, advertised boldly in the newspapers and phone books as permanent makeup

for a beautiful personal investment (Armstrong & Fell, 2000).

Historically, the Japanese have used handheld, non-mechanized instruments to apply intricate tattoos, which often cover large portions of the body. Polynesia and Japan are believed to be responsible for the introduction of modern tattooing into Western cultures via the exposure of European and American sailors to these practices while on commercial or naval visits cosmetic body piercing, electrolysis and tattooing activities (Scottish Executive Health Department (SEHD), 2001).

## II. BODY PIERCING AND TATTOOING

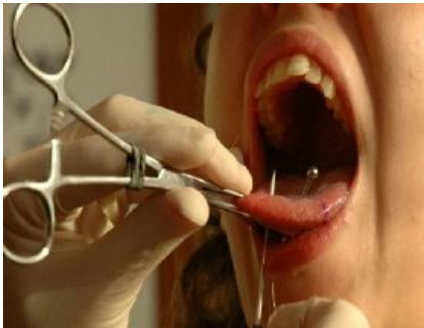Tattooing and body piercing showed a raise from the 90s and the trend does not show signs of decreasing in the near future. Adolescents and young adults have increasingly acquired body piercing over recent years and medical literature in relation to prevalence of P is partially still limited. (Gold, Schorzman, Murray, 2005).

Often terms such as piercing, body piercing, skin piercing and cosmetic body piercing are used interchangeably. Although, skin piercing is now used more frequently in its widest sense to include acupuncture. Tattooing and body piercing have become increasingly popular and fashionable in recent years, particularly among young adolescents. Jewellery and body adornment may reflect culturally defined notions of beauty for particular groups. In UK, ear lobe piercing has been accepted for many years. The piercing of other body parts is a more recent trend, whatever the reasons for choosing body adornment, it can have serious health implications, which adolescent and healthcare workers should be made aware of. Health risks include localized infection, systemic infection and skin reactions (Jane, 2003).

Raspa and Cusack cited in Schmidt & Armstrong (2011) argue that, many healthcare professionals associate body art with criminal activity or psychiatric disturbance, based in part on some early descriptive studies some are still trying to make that case. Individuals often associate tattoos and body piercings with gang members, prisoners, military personnel or rebellious teenagers (Carrollet. al., 2002 and Roberts & Ryan, 2002).

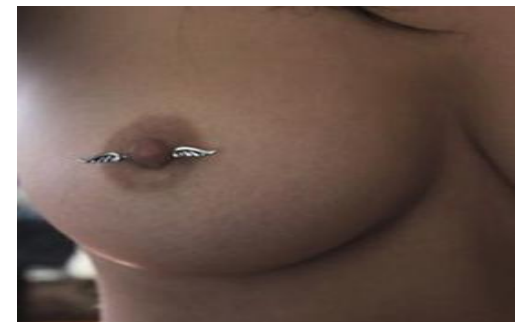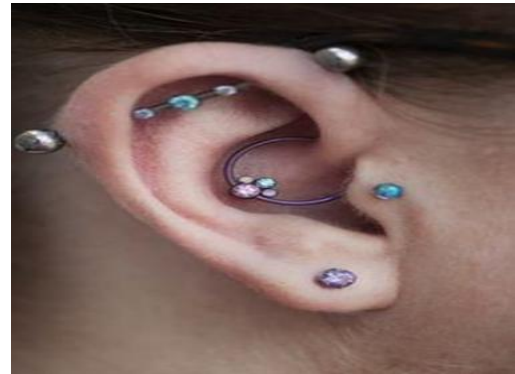In reality, a variety of people, including professionals, clergy or other “respected members of society” acquire body art for an assortment of reasons. Unfortunately, a healthcare professional’s negative attitude about body art may interfere with the optimal treatment of patients with these types of ornamentation (Kuchinski, Pereira & Armstrong, 2006).

- What is body piercing?



Body piercing was often identified with royalty and portrayed courage and virility. Egyptian Pharaohs pierced their nipples to show their manhood and Mayans pierced their tongues as a spiritual ritual.

Body piercing is when a hole is made in your skin so you can add a piece of jewelry for decoration. Tooth chipping and gum damage can happen in people with tongue and lip piercings. Jewelry in the mouth or nose can be swallowed accidentally (America Family Physician, 2005).



- What is Tattooing?

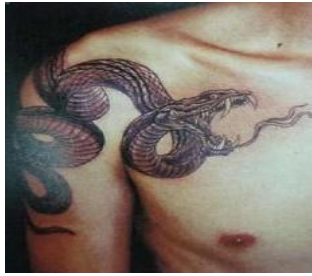Over the years, tattoos have become little more than decaling the human skin. Most people get a tattoo and spent there whole life never knowing the true meaning. Others are confused on the meanings of tattoos and get something that might have a completely different definition. Tattooing has been a part of every culture known to date, and each culture has its own meanings for different images. Here is a list of tattoo images that have meanings you may be surprised of. There are so many images to choose from, I am forced to pick from a few of thousands. When you offer a tattoo to a client, or choosing one for yourself, you should always research the true meaning (Richard, 2008).

BAT




Longevity, happiness, mystery

SNAKE



Temptation, knowledge, and wisdom

REAPER



Death or one has faced death

SKULL



Courage, Death, Poison

MERMAID



Temptation, seduction, materialism

• What is Adolescent?

Adolescence describes the teenage years between 13 and 19 and can be considered the transitional stage from childhood to adulthood. However, the physical and psychological changes that occur in adolescence can start earlier, during the preteen or "tween" years (ages 9 through 12). Adolescence can be a time of both disorientation and discovery. The transitional period can bring up issues of independence and self-identity; many adolescents and their peers face tough choices regarding schoolwork, sexuality, drugs, alcohol, and social life. Peer groups, romantic interests, and external appearance tend to naturally increase in importance for some time during a teen's journey toward adulthood.

Trends in the growth of the adolescent age group vary markedly by region. The population of adolescents has already peaked in the developed world and in Eastern and South Eastern Asia, while the adolescent population is not projected to peak until 2010 in Latin America and the Caribbean and until 2025 and 2030 in South Central Asia and West Asia respectively. In sub-Saharan Africa, the population of adolescents is projected to still be growing in 2050 (Population Division of the Department of Economic and Social Affairs of the United Nations Secretariat, 2009).

• What prompt adolescent into tattooing and body piercing?

The finding shows that the reason that prompts the young adolescent into body piercing and tattooing includes but not limited to the following:

- i. Individualism
- ii. Sexual fantasies
- iii. Uniqueness
- iv. sexual expression and/or sexual stimulation.

• Health risks/ side effect associated with body piercing and tattooing.

Body piercing and tattoo are associated with health risks, yet the medical literature lacks data on the incidence of these dangers compared with the overall incidence of body art (Armstrong & Kelly, 2001).

The result of a study conducted by Long and Rickman as cited by Schmidt\_& Armstrong (2011)

reveals that, most health risks are related to infectious complications or localized skin reactions, but the potential of blood-borne diseases is present.

There is sufficient literature to suggest that the spread of Blood-Borne Viruses (BBV) may be a risk associated with tattooing, body piercing and some complementary therapies such as acupuncture (Haley & Fischer, 2001; Nishioka & Gyorkos, 2001). There is particular concern about the potential for the spread of hepatitis C. Several guidelines highlight additional health hazards from body piercing and tattooing which includes:

- Localized infection

Body piercing and tattooing may be associated with localized skin infection due to *Staphylococcus aureus* and other organisms, including atypical mycobacteria (Drage, Ecker & Orenstein, 2010, CDC, 2006 and Kappel & Cotliar, 2011). The risk of infection is greater in individuals with newly acquired body pierce or tattoos because of diminished skin integrity following the procedure.

- HIV infection

Many healthcare providers consider body piercing or tattooing to be a risk factor for HIV infection. Although HIV may be transmitted through body piercing and tattooing methods, the relationship needs to be more clearly defined. (Armstrong, Roberts & Koch, 2008).

- Skin reactions

Generalized skin reactions, such as acquired hypersensitivity reactions to the tattoo pigment, can occur (Dron, Lafourcade & Leprince (2007).

In one study, samples of 30 tattoo inks were chemically analyzed and results compared with the information supplied by the manufacturer (Timko, Miller, Johnson & Ross, 2001). Among the 30 pigment samples, the most commonly identified

elements were aluminum (87 percent), oxygen (73 percent), titanium (67 percent), and carbon (67 percent). The elemental analysis was usually consistent with the information supplied by the manufacturer, but there were important exceptions. Further research indicates that some pigments are industrial-grade colors suitable for printers' ink or automobile paint (Engel, Santarelli & Vasold, 2008). A study conducted by Armstrong (2005), shows that most tattoo pigment manufacturers do not provide a description of the enclosed materials, but one state (California) requires that tattoo pigments provide an itemization of ingredients

Less common skin reactions that may occur with tattooing include sarcoidal reactions, scleroderma, keloid formations, and hypertrophic scars (Schmidt & Armstrong, 2011).

- Hypersensitivity reactions

Delayed hypersensitivity reactions localized to the site of ink injection are well described in association with red (mercury), green (chromium), yellow (cadmium), and blue (cobalt) tattoo pigments (Neri, Guareschi, Savoia & Patrizi, 2002).

- Hepatitis

Hepatitis B and C can be transmitted during body piercing or tattooing via reused or inadequately sterilized instruments (Hayes & Harkness, 2001, Haley & Fischer, 2001). In a meta-analysis of 83 studies by Jafari, Copes and Baharlou (2010), the pooled odds ratio of hepatitis C among body pierce and tattoo recipients was 2.74 (95 % CI 2.38-3.15).

- Systemic infection

Systemic infection complicates tattoos less frequently than local infection. Systemic infection is more likely to occur in people who have had amateur tattoos or have not followed the after-care instructions. In the past, syphilis was transmitted by tattooists who held the needles in their mouths or used saliva to mix pigments.

- Other reactions

- Blood poisoning;
- Localised severe swelling and trauma around the piercing site;

- Scarring;
- Allergic reactions to metals and antiseptics;
- Severe bleeding.
  
- Advice for the young adolescent
  - ✓ The body art should be included as a routine topic addressed by family physicians and school administrators for young adolescents and adults.
  - ✓ When carefully made, may help lower their risk of experiencing the most commonly documented adverse effects of body piercing and tattooing. More accurate information (Figure) can be provided to young adolescents than they often receive from friends and professional body artists.
  - ✓ An important factor in body piercing is the sterilisation of jewellery immediately prior to insertion.
  - ✓ New needles should be used for each body piercing or tattooing and by selecting a studio with an educated artist

- Summary

Body piercing and tattooing are two categories of skin piercing, which fall within the wider phenomena of body art, adornment or modification – all terms used to describe activities that alter the human body in either a permanent or semi-permanent yet deliberate way for non-medical reasons. There are known and well reported health risks which can be attributed to body piercing and tattooing, as well as associated legal issues. Improper and unhygienic practice may result in localized skin infections at the site of the tattooing or piercing.

There is also the risk of transmission of blood-borne viruses, for example Hepatitis B, Hepatitis C, Hepatitis D or HIV, which can have more serious and long term health consequences. It is therefore important that practitioners have safe working practices and particularly that good infection control practices are followed at all times, so that both adolescent and body art practitioners are protected.

#### CONCLUSIONS

Several authors have identified a range of skills and knowledge among tattooists and body piercers

(Carroll and Beard, 2000). Although, information on the range of body adornment and advice for prospective adolescent are available on the internet, schools may need to make some of the health messages accessible to their pupils.

Family physicians continually face challenges in providing up-to-date guidance for their patients. The fact that over half of participants reported at least one body piercing—and mounting evidence that this behavior is associated with increased health risks as well as other potentially risky behaviors.

Physicians who provide primary healthcare at routine and precollege physical examinations are ideally situated to provide patient education to this population—as administrators at college and university campus-orientation meetings, health fairs, and in other health services venues e.g. waiting areas, examination rooms (Carroll, Riffenburgh, Roberts & Myhre, 2007).

#### RECOMMENDATIONS

Although, young adolescents and adults already perceive the risks of body piercing as quite high, they may not be fully aware of the effect of their choices when pursuing this form of self-expression, specifically in their selection of certain anatomic sites instead of others for body piercing (Martel & Anderson, 2007).

The risk of localized infection can be reduced when the individual receiving the body pierce and tattoo understands the procedure, obtains it in a studio that uses sterile procedures, and follows appropriate after-care instructions regarding cleaning and maintenance. We suggest soap and water as an appropriate after-care solution.

Certainly, the risk of contracting either hepatitis or HIV can be reduced by using new needles with each body piercing or tattooing and by selecting a studio with an educated artist.

An important factor in body piercing is the sterilization of jewellery immediately prior to insertion. The sterilization of packaged jewellery in a standard steam sterilizer was identified by Barnett et al (2003) as a risk. Unless a vacuum sterilizer is used,

which will penetrate packaging, the jewellery may not be sterile at the point of use. Piercers were therefore advised to sterilize jewellery immediately before insertion

REFERENCES

- [1] America Family Physician (2005). Information from your family doctor. Retrieved from <http://www.aafp.org/afp/2005/1115/p2035.html>
- [2] Armstrong, M.L. (2005). Tattooing, body piercing, and permanent cosmetics: a historical and current view of state regulations, with continuing concerns. *J Environ Health*. 67:38.
- [3] Armstrong, M.L. and Kelly, L. (2001). Tattooing, body piercing, and branding are on the rise: perspectives for school nurses. *J SchNurs*. Vol. 17. Pg. 12.
- [4] Armstrong, M.L., & Fell, R.P. (2000). Body art: Regulatory issues and the NEHA Body Art Model Code, *Journal of Environmental Health*, 62(9), 25-30.
- [5] Armstrong, M.L., Roberts, A.E. and Koch, J.R., (2008). Motivation for contemporary tattoo removal: a shift in identity. *ArchDermatol*.
- [6] Carroll, S.T., Riffenburgh, R.H. Roberts, T.A. and Myhre, E.B. (2002). Tattoos and body piercings as indicators of adolescent risk-taking behaviors. *Pediatrics*. 109:1021.
- [7] Carroll, S.T., Riffenburgh, R.H., Roberts, T.A. and Myhre EB. (2007). Tattoos and body piercings as indicators of adolescent risk-taking behaviors. *Pediatrics*. 109:1021-1027. Retrieved from <http://pediatrics.aappublications.org/cgi/content/full/109/6/1021>.
- [8] Centers for Disease Control and Prevention (2006). Methicillin-resistant *Staphylococcus aureus* skin infections among tattoo recipients-Ohio, Kentucky, and Vermont, 2004-2005. *MMWR Morb Mortal Wkly Rep*. 55:677.
- [9] Drage, L.A., Ecker, P.M. and Orenstein, R. (2010). An outbreak of *Mycobacterium chelonae* infections in tattoos. *J Am AcadDermatol* 62:501.
- [10] Dron, P., Lafourcade, M.P., Leprince, F., (2007) Allergies associated with body piercing and tattoos: a report of the Allergy Vigilance Network. *Eur Ann Allergy ClinImmunol*. 39:189.
- [11] Engel, E., Santarelli F. and Vasold, R., (2008). Modern tattoos cause high concentrations of hazardous pigments in skin. *Contact Dermatitis*. 58:228.
- [12] Gold M.A., Schorzman C.M. and Murray P.J., (2005). Body piercing practices and attitudes among urban adolescents. *J Adolesc Health*. 36:352. 17-4.
- [13] Haley, R.W. and Fischer, R.P. (2001). Commercial tattooing as a potentially important source of hepatitis C infection. *Clinical epidemiology of 626 consecutive patients unaware of their hepatitis C serologic status. Medicine (Baltimore)*, 80:134.
- [14] Hayes, M.O. and Harkness, G.A. (2001). Body piercing as a risk factor for viral hepatitis: an integrative research review. *Am J Infect Control*. 29:271.
- [15] Jafari, S., Copes, R., and Baharlou S. (2010). Tattooing and the risk of transmission of hepatitis C: a systematic review and meta-analysis. *Int J Infect Dis*, 14:928.
- [16] Jane B. (2003). Health implications of body piercing and tattooing: a literature review. Gloucestershire Health Protection Unit, Cheltenham. VOL: 99, (37). Pg. 62
- [17] Kappel, S. and Cotliar, J. (2011). Inoculation of *Mycobacteria chelonae* from a tattoo. *J Am Acad Dermatol*. 64:998.
- [18] Kuchinski, A., Pereira, P. and Armstrong, M.L. (2006). Caring for piercing clients: Attitudes, secondary trauma and forensic evidence. *Mosby's Nursing Consult*.
- [19] Martel S. and Anderson, J.E. (2007). Decorating the "human canvas": body art and your patients. *ContempPediatr*. 2002;19:86-102. Retrieved from <http://www.contemporarypediatrics.com/contpeds/content/contentDetail.jsp?id=126651>.

- [20] Neri I., Guareschi, E., Savoia, F. and Patrizi, A. (2002). Childhood allergic contact dermatitis from henna tattoo. *PediatrDermatol.* 19:503.
- [21] Nishioka, S.A and Gyorkos, T.W. (2001). Tattoos as risk factors for transfusion-transmitted diseases. *Int J Infect Dis.*, 5(1), 27 - 34.
- [22] Population Division of the Department of Economic and Social Affairs of the United Nations Secretariat (2009). *World Population Prospects: The 2008 Revision.*<http://esa.un.org/unpp>. (GENERIC).
- [23] Richard L. (2008). *The Body Modification. Black Book: A Guide for Students of Body Modification.* Retrieved from<http://www.ink-trails.com>
- [24] Roberts, T.A. and Ryan, S.A. (2002). Tattooing and high-risk behavior in adolescents. *Pediatrics.* 110:1058.
- [25] Schmidt, R. M. and Armstrong, M. L. (2011). *Tattooing in adolescents and young adults.* UPtoDate. Retrieved from <http://cursoenarm.net/UPTODATE/contents/>
- [26] Scottish Executive Health Department (SEHD) (2001). *Regulation of skin piercing: a consultation paper.* Edinburgh: Stationery Office.
- [27] Timko, A.L., Miller, C.H., Johnson, F.B. and Ross, E. (2001). *In vitro quantitative chemical analysis of tattoo pigments.* *Arch Dermatol.* 137:143. Retrieved from [mobipreview.htm?38/](http://mobipreview.htm?38/)